

Soft Tissue Ridge Augmentation Around Implant Using Modified Pouch Approach: A Case Report

APARNA KAUSHIK¹, NISHI TANWAR², RAJINDER KUMAR SHARMA³, SHIKHA TEWARI⁴

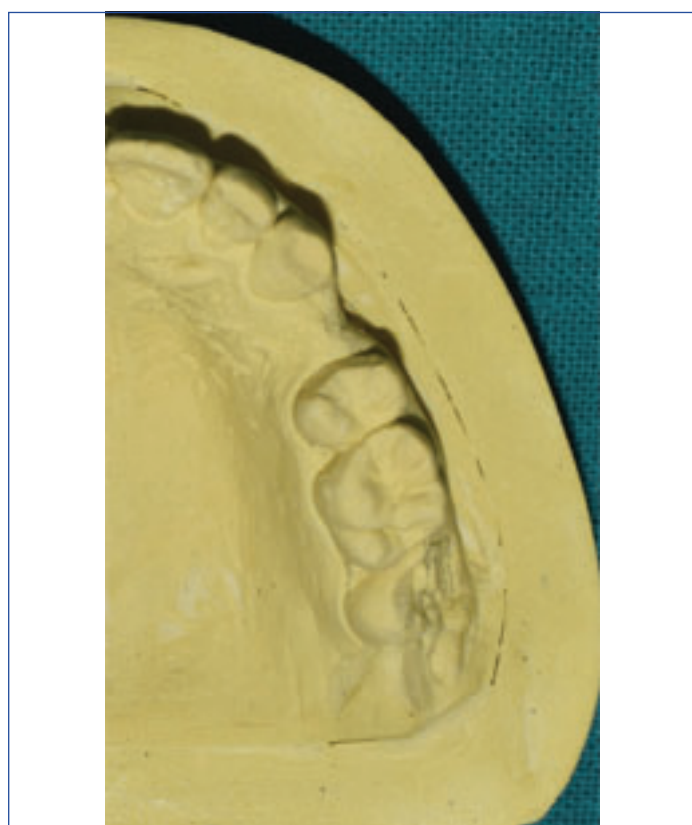ABSTRACT

Common clinical findings around dental implants are hard and soft tissue defects requiring interventions for functional and aesthetic purposes. Interventions include hard as well as soft tissue augmentation. Present case management included subepithelial connective tissue grafting with modification of lateral pouch graft procedure, avoiding the vertical incisions. To the best of our knowledge, this is the first case report of this modified procedure. A 24-year-old female patient was referred by the prosthodontist for soft tissue augmentation after implant placement with respect to #24. With the consent of patient, subepithelial connective tissue graft was placed using modified lateral pouch graft procedure. Patient was evaluated at three months. Adequate soft tissue thickness was obtained with satisfactory results. This modified pouch graft procedure is expected to provide better aesthetic results. This procedure can be best utilised for small horizontal ridge defects. This is a novel approach for soft tissue augmentation without using vertical incisions thus providing better aesthetic results. Further studies are suggested regarding the long term success of the procedure.

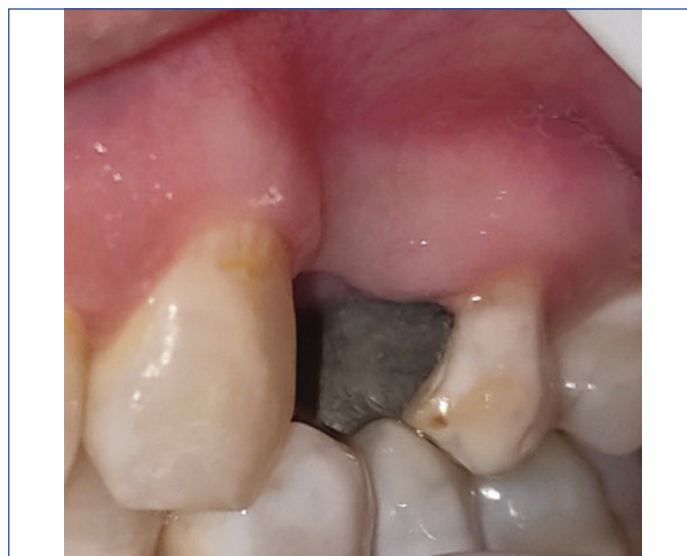Keywords: Alveolar ridge augmentation, Complications, Dental aesthetics, Dental implants

CASE REPORT

A 24-year-old female patient was referred by the prosthodontist for soft tissue augmentation after implant placement with respect to edentulous space of upper right first premolar. Implant was placed six months back along with bone grafting with respect to #24 for hard tissue augmentation. On intraoral examination, Seibert Class-I defect (horizontal ridge deficiency) [1] was found at the site [Table/Fig-1,2]. Adequate keratinised tissue thickness was present at the ridge defect site. Intraoral peri-apical radiograph [Table/Fig-3]

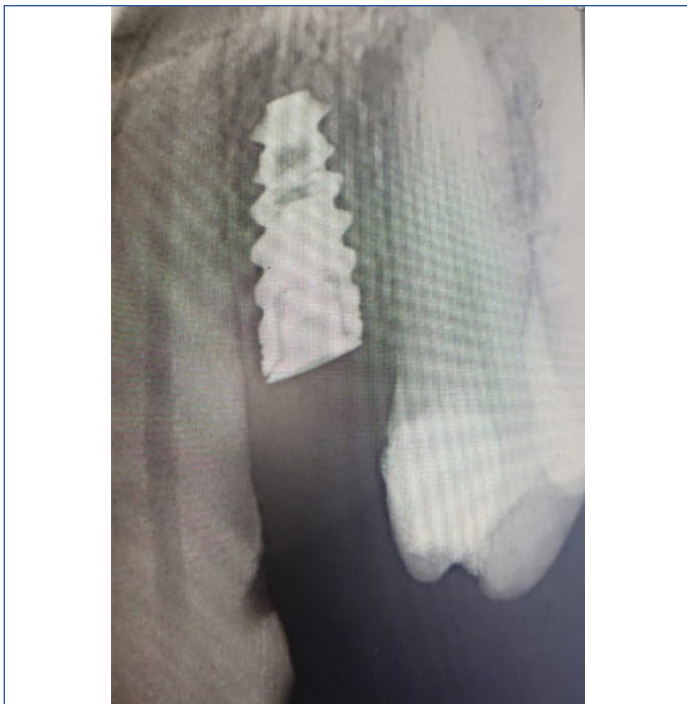

[Table/Fig-1]: Preoperative cast model revealing seibert Class-1 ridge defect with respect to first premolar.

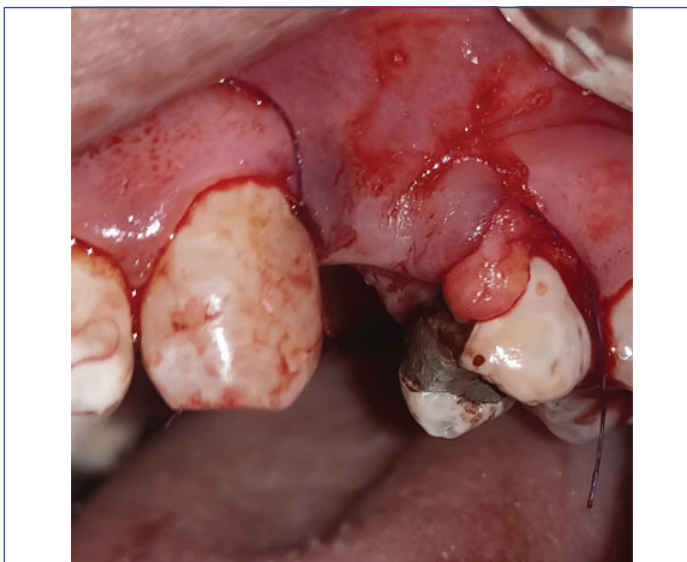


[Table/Fig-2]: Preoperative clinical picture revealing seibert Class-1 ridge defect with respect to first premolar.

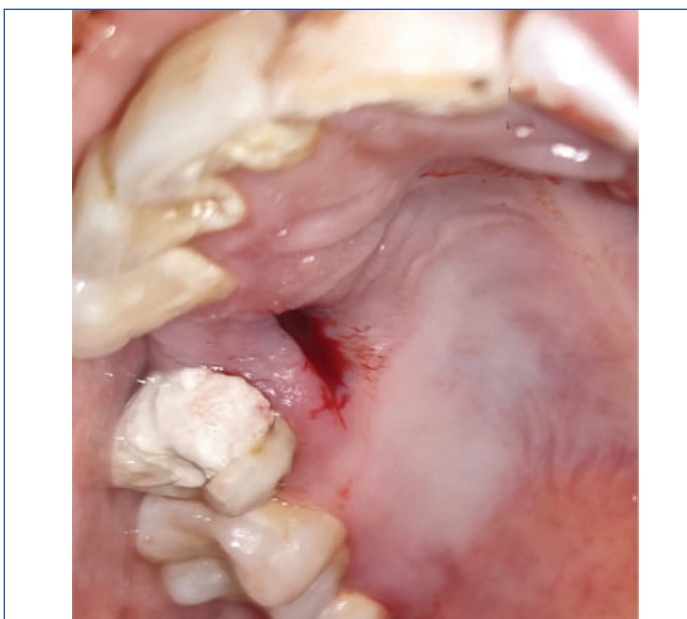
was taken to assess osseointegration of the implant, and to rule out any periodontal and peri-apical infection of the adjacent teeth. Periodontal tissue was healthy on clinical and radiographic examination [Table/Fig-3,4]. Soft tissue ridge augmentation procedure using subepithelial connective tissue with a modification of pouch graft approach was planned. Patient was informed about the procedure and consent was taken. Medical and dental history was non-contributory. Full mouth scaling was done. Patient was recalled after one week for the procedure. After anaesthetising concerned area, sulcular incisions were made on the distal line angle of canine and mesial line angle of 2nd premolar using Bard Parker blade (#15C). Sub-epithelial tunnel was prepared using Urban's knife and periosteal elevator relieving all the underneath fibers. Sub-epithelial connective tissue graft of size 5×8 mm was retrieved from right-side of palate from premolar region [Table/Fig-5] using single incision technique. Graft was inserted in the tunnel [Table/Fig-4] and was secured with tooth anchored sutures using 5-0 prolene suture. Aftercare included antibiotics (Amoxicillin 500 mg thrice daily for



[Table/Fig-3]: Intraoral peri-apical radiograph.

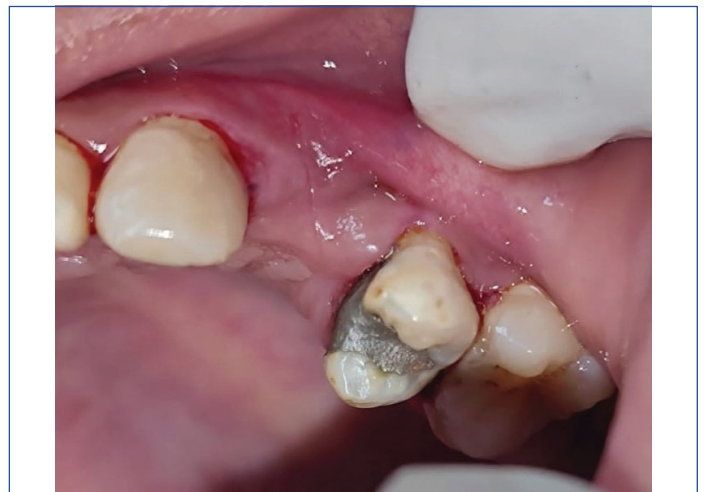

[Table/Fig-4]: Intraoperative picture showing insertion of graft in the sub-epithelial tunnel.

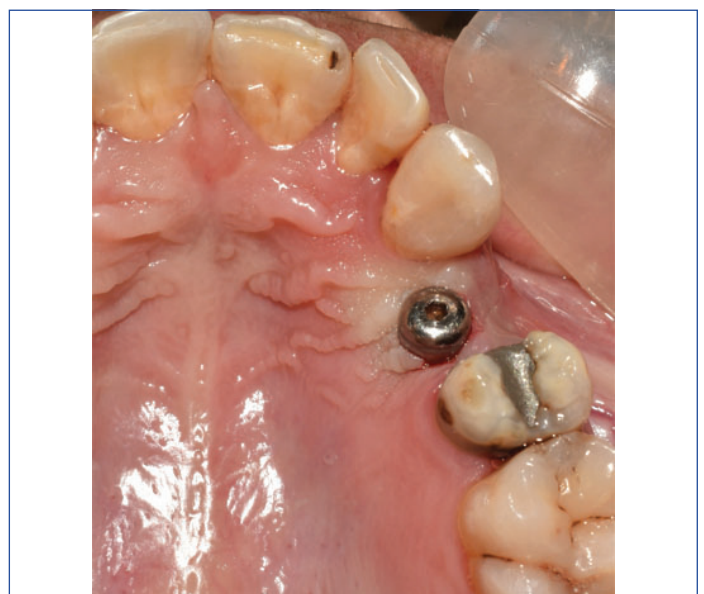

[Table/Fig-5]: Graft harvested site on right-side of palate.

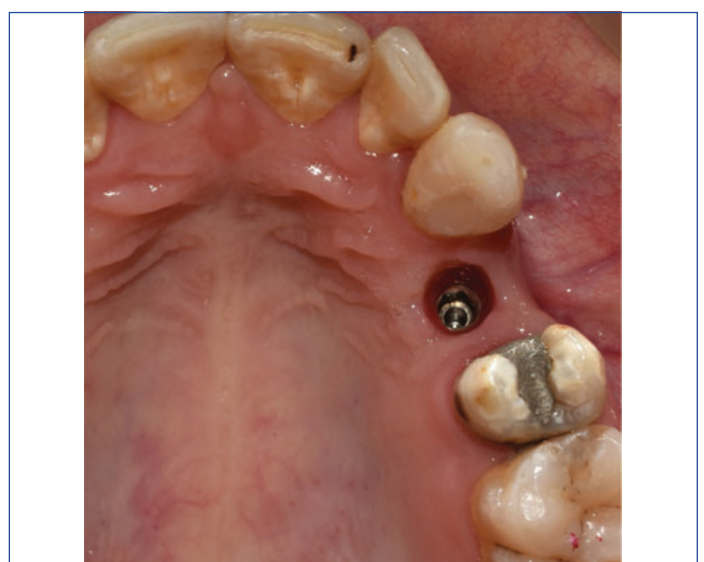
five days) and analgesics (Ibuprofen 400 mg twice daily for three days) and chlorhexidine mouthwash 0.2% twice daily for two weeks. Suture removal was done after 10 days [Table/Fig-6]. Patient was recalled at one month [Table/Fig-7] and three months [Table/Fig-8,9]. Significant amount (3 mm) of soft tissue buldge was obtained at the concerned site. Patient was satisfied with the outcome. Results were stable till three months [Table/Fig-10]. Patient is still on follow-up.



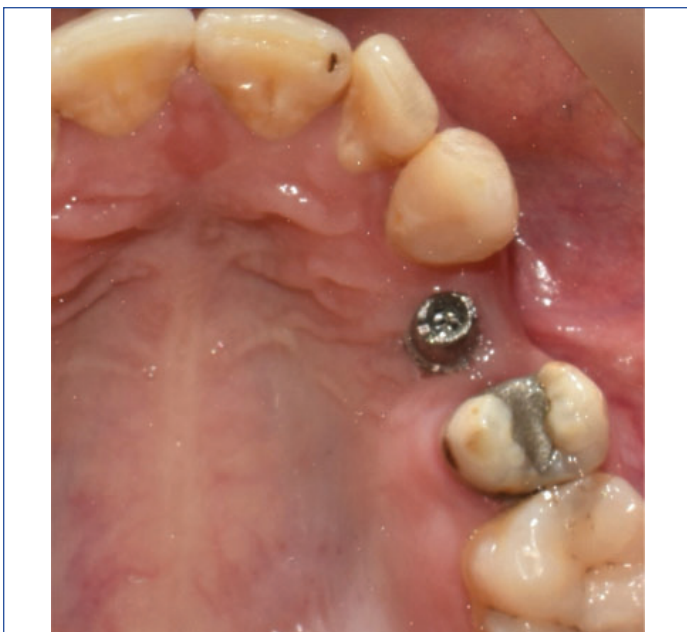[Table/Fig-6]: After suture removal.



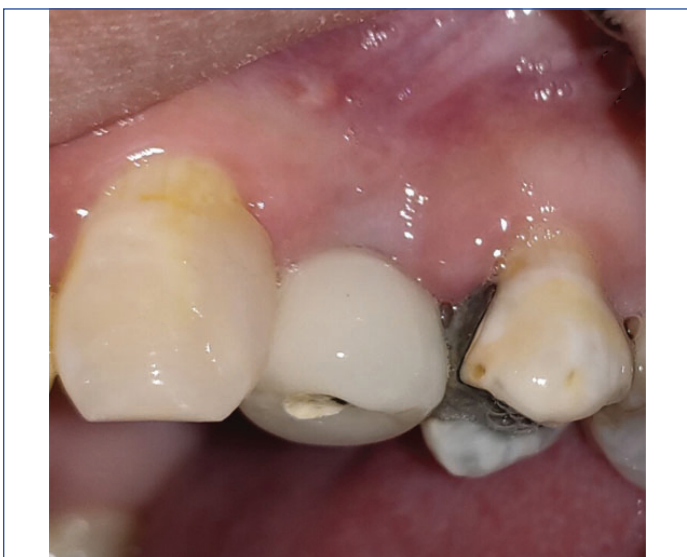[Table/Fig-7]: One month follow-up with healing abutment.



[Table/Fig-8]: One month follow-up after removal of healing abutment.



[Table/Fig-9]: One month follow-up with placement of prosthetic abutment.



[Table/Fig-10]: Three month follow-up with prosthesis.

DISCUSSION

Hard and soft tissue deficiencies are common clinical findings around dental implant, included in the new classification of periodontal and peri-implant diseases and conditions under category "Peri-Implant soft and hard tissue deficiencies" [2]. Very well evidenced contributing factor for tissue defects is tooth loss [3] leading to some physiological changes in hard as well as soft tissue of the alveolar bone. Majority of changes take place within first year [4]. Reduction in buccal tissue volume, noted frequently, [5] is a physiologic phenomenon which can be explained on the basis of difference in thickness of buccal and lingual/palatal bony plates. Ridge concavity created as a result of volume loss, many times become reason of aesthetic concern for patient as well as clinician. Also, it is difficult to provide a good functional prosthesis on a deficient ridge. Ridge augmentation procedures are evolving as solution for ridge deficiency. Both hard as well as soft tissue augmentation can be performed in some deficient ridge cases. Various types of prosthesis such as Maryland bridges can also be provided to compensate for deficient volume of ridge [6]. Soft tissue augmentation procedures demonstrated for this purpose are: roll flap procedure, pouch graft procedure, interpositional graft procedure and onlay graft procedure. On the basis of short term evaluation of results in term of volumetric increase in edentulous ridge, Studer S et al., proposed these procedures as: roll flap

procedure for single tooth ridge defect (minor horizontal and vertical loss) correction, submerged connective tissue graft for larger defects, onlay full thickness gingival graft for ridge augmentation with mucogingival problems [7]. Studer SP et al., demonstrated superior results with the use of submerged connective tissue grafts compared to the use of full thickness graft [8].

Pouch graft procedure is used to correct Class-I ridge defects. Initial incision and dissection plane may vary [9,10]. When the dissection plane is lateral, one or two vertical incisions are made from either side of the defect.

This lateral plane dissection pouch graft procedure with one vertical incision was demonstrated by Kaldahl WB et al., [11]. The procedure used in present case is although based on the same principle as of lateral pouch graft procedure but is a modification of this technique as approach was through adjacent gingival sulcus without any vertical incision.

As in this case, hard tissue augmentation was done prior to implant placement, option left to counter the ridge deficiency was soft tissue augmentation. It can be done at different time points for the implant, although a systematic review [12] revealed significant enhancement in soft tissue thickness and keratinised tissue width at three months regardless of procedural timings.

In present case, soft tissue ridge augmentation procedure was done three weeks before the second stage surgery using autogenous subepithelial connective tissue graft which is considered as gold standard. After three months, satisfactory results were obtained [Table/Fig-5] and were stable. However, one clinical trial reported analogous results using new xenograft materials [13], another reported better results with connective tissue graft [14].

In present case, surgical procedure was performed using sulcular incision avoiding any vertical incision. Vertical incisions should be avoided in the anterior region as it leads to scarring, compromising the aesthetics.

This modified technique can be used in Class-1 ridge defect with small edentulous span (involving one tooth). Advantages of this technique include better aesthetics and less postoperative complications due to adequate blood supply, minimum tissue trauma thereby imparting early uneventful healing. Limitation of this procedure can be stated as that this procedure may not be performed in larger edentulous span due to limited availability of connective tissue graft and also subepithelial tunnel cannot be prepared for long edentulous span.

CONCLUSION(S)

This case report presents modification of lateral pouch graft procedure for soft tissue ridge construction in the maxillary premolar area having horizontal ridge defect. No vertical incision, good blood supply, less tissue trauma, use of autogenous graft contributed to the success of this procedure in terms of aesthetics, but limited availability of the connective tissue adds limitation to this procedure for long edentulous span. Further, long term follow-ups are advised for such cases to observe the dimensional stability.

Acknowledgement

We acknowledge Post Graduate Institute of Dental Sciences, Rohtak for providing all the facilities to conduct this research and Dr. Sujata Chahal from Department of Prosthodontics for referring and providing clinical details.

REFERENCES

- [1] Seibert JS. Reconstruction of deformed, partially edentulous ridges, using full thickness onlay grafts. Part II. Prosthetic/periodontal interrelationships. *Compend Contin Educ Dent (Lawrenceville)*. 1983;4(6):549-62.
- [2] Caton JG, Armitage G, Berglundh T, Chapple ILC, Jepsen S, Kornman KS, et al. A new classification scheme for periodontal and peri-implant diseases and conditions-Introduction and key changes from the 1999 classification. *J Clin Periodontol*. 2018;45:S1-08.

- [3] Tan WL, Wong TLT, Wong MCM, Lang NP. A systematic review of post-extraction alveolar hard and soft tissue dimensional changes in humans. *Clin Oral Implants Res.* 2012;23 Suppl 5:01-21.
- [4] Schropp L, Wenzel A, Kostopoulos L, Karring T. Bone healing and soft tissue contour changes following single-tooth extraction: A clinical and radiographic 12-month prospective study. *Int J Periodontics Restorative Dent.* 2003;23(4):313-23.
- [5] Araujo MG, da Silva JCC, de Mendonça AF, Lindhe J. Ridge alterations following grafting of fresh extraction sockets in man. A randomized clinical trial. *Clin Oral Implants Res.* 2015;26(4):407-12.
- [6] Malament KA, Neeser S. Prosthodontic management of ridge deficiencies. *Dent Clin North Am.* 2004;48(3):735-44, vii.
- [7] Studer S, Naef R, Schärer P. Adjustment of localized alveolar ridge defects by soft tissue transplantation to improve mucogingival esthetics: A proposal for clinical classification and an evaluation of procedures. *Quintessence Int.* 1997;28(12):785-805.
- [8] Studer SP, Lehner C, Bucher A, Schärer P. Soft tissue correction of a single-tooth pontic space: A comparative quantitative volume assessment. *J Prosthet Dent.* 2000;83(4):402-11.
- [9] Miller PD. Ridge augmentation under existing fixed prosthesis. Simplified technique. *J Periodontol.* 1986;57(12):742-45.
- [10] Allen EP, Gainza CS, Farthing GG, Newbold DA. Improved technique for localized ridge augmentation. A report of 21 cases. *J Periodontol.* 1985;56(4):195-99.
- [11] Kaldahl WB, Tussing GJ, Wentz FM, Walker JA. Achieving an esthetic appearance with a fixed prosthesis by submucosal grafts. *J Am Dent Assoc.* 1939. 1982;104(4):449-52.
- [12] Lin CY, Chen Z, Pan WL, Wang HL. Impact of timing on soft tissue augmentation during implant treatment: A systematic review and meta-analysis. *Clin Oral Implants Res.* 2018;29(5):508-21.
- [13] Zeltner M, Jung RE, Hämmerle CHF, Hüsler J, Thoma DS. Randomized controlled clinical study comparing a volume-stable collagen matrix to autogenous connective tissue grafts for soft tissue augmentation at implant sites: Linear volumetric soft tissue changes up to 3 months. *J Clin Periodontol.* 2017;44(4):446-53.
- [14] Cairo F, Barbato L, Tonelli P, Batalocco G, Pagavino G, Nieri M. Xenogeneic collagen matrix versus connective tissue graft for buccal soft tissue augmentation at implant site. A randomized, controlled clinical trial. *J Clin Periodontol.* 2017;44(7):769-76.

PARTICULARS OF CONTRIBUTORS:

1. Postgraduate Student, Department of Periodontology, PGIDS, Rohtak, Haryana, India.
2. Professor, Department of Periodontology, PGIDS, Rohtak, Haryana, India.
3. Senior Professor and Head, Department of Periodontology, PGIDS, Rohtak, Haryana, India.
4. Senior Professor, Department of Periodontology, PGIDS, Rohtak, Haryana, India.

NAME, ADDRESS, E-MAIL ID OF THE CORRESPONDING AUTHOR:

Dr Nishi Tanwar,
Professor, Department of Periodontology, Post Graduate Institute of Dental Sciences,
Rohtak-124001, Haryana, India.
E-mail: aparna81112@gmail.com; nsh_tanwar@yahoo.co.in

PLAGIARISM CHECKING METHODS: [Jain H et al.]

- Plagiarism X-checker: Oct 6, 2022
- Manual Googling: Feb 02, 2023
- iThenticate Software: Feb 18, 2023 (8%)

ETYMOLOGY: Author Origin**EMENDATIONS:** 5**AUTHOR DECLARATION:**

- Financial or Other Competing Interests: None
- Was Ethics Committee Approval obtained for this study? Yes
- Was informed consent obtained from the subjects involved in the study? Yes
- For any images presented appropriate consent has been obtained from the subjects. Yes

Date of Submission: **Oct 15, 2022**Date of Peer Review: **Jan 25, 2023**Date of Acceptance: **Feb 20, 2023**Date of Publishing: **Jun 01, 2023**